

Varicose Veins

Presented by:

Dr. John Bergseng, General Surgery

November 18, 2010

Acknowledgment

The following slides and information are courtesy of:
Covidien/Vnus Medical Technologies

www.vnus.com

GRHS would like to thank them for providing
these educational materials for this health talk.

Important Notice

The information contained in this document is for informational purposes only. It is not intended to diagnose or treat specific patients and should not be used as a substitute for the medical care and advice of your health care provider. In addition, this document may contain references to specific products and/or medications. Such references, whether by brand name or generically, are provided for informational purposes only and do not constitute endorsement, recommendation, or approval by GRHS or its medical providers. Always consult a medical professional if you have concerns regarding your health. If you are experiencing a medical emergency, dial 911.

Due to copyright and other considerations, some images may have been removed from the original presentation.

- Video

Circulatory System

- Body has 60 thousand miles of blood vessels, a distance of nearly 2 ½ times around the earth at the equator
- Entire body has 70 thousand square feet of capillary wall
- Artery -> Arteriole -> Capillary -> Venule -> Vein
- 190 capillaries in each square mm of muscle
- Capillary diameter same width as RBC
- Capillary wall exchange water, glucose, electrolytes, oxygen, carbon dioxide, & small proteins.
- Capillary wall tension to rupture is one three-thousandths of that needed to tear toilet paper.

- It is well known that blood contains white and red cells. But it is not so well known that white cells come in husband and wife forms. Evidence for this came when the renown medical researcher Dr. Sanguine listened to blood with a tiny microphone and heard a white wife cell say, “The way to a man’s heart is through his veins.”

Circulation

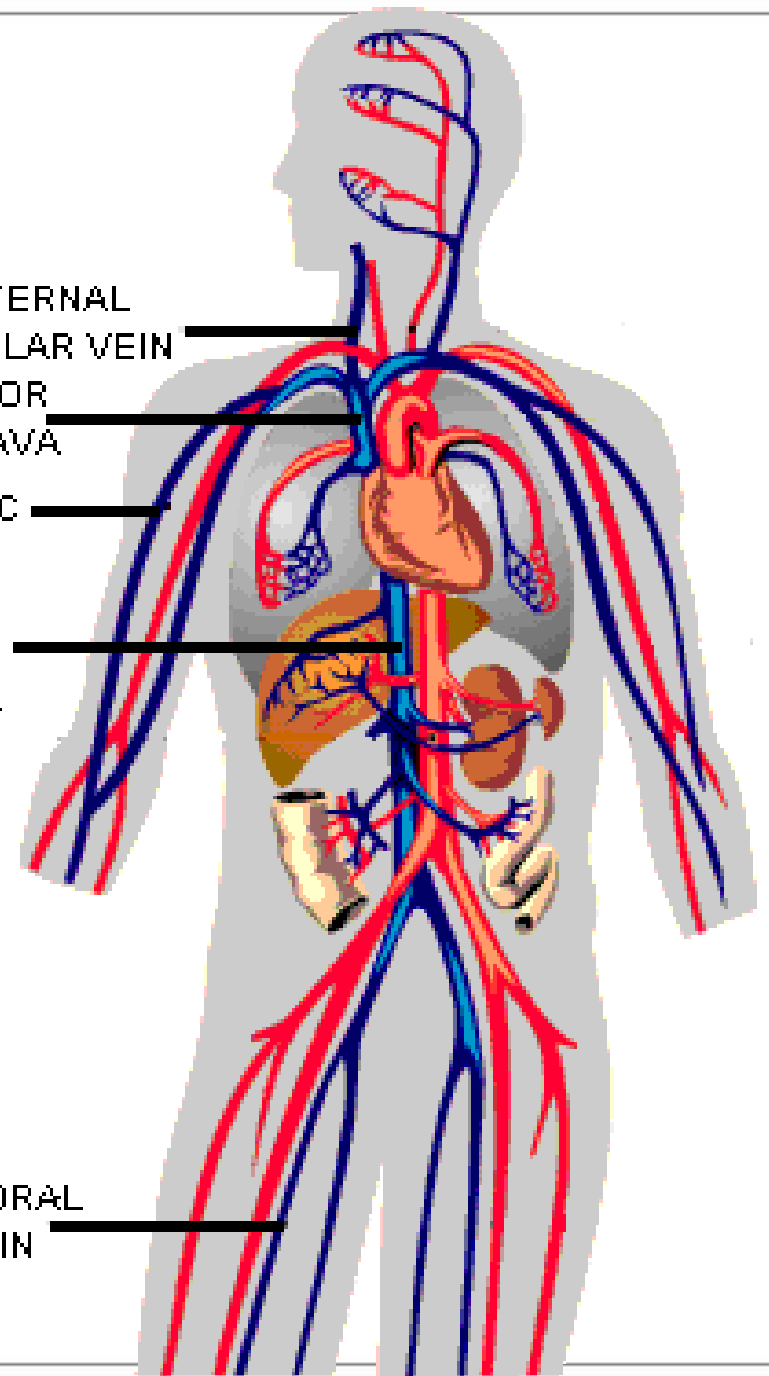
INTERNAL
JUGULAR VEIN

SUPERIOR
VENA CAVA

CEPHALIC
VEIN

INFERIOR
VENA CAVA

FEMORAL
VEIN




Jay Walking

Jay Leno: “How does blood circulate in the human body?”

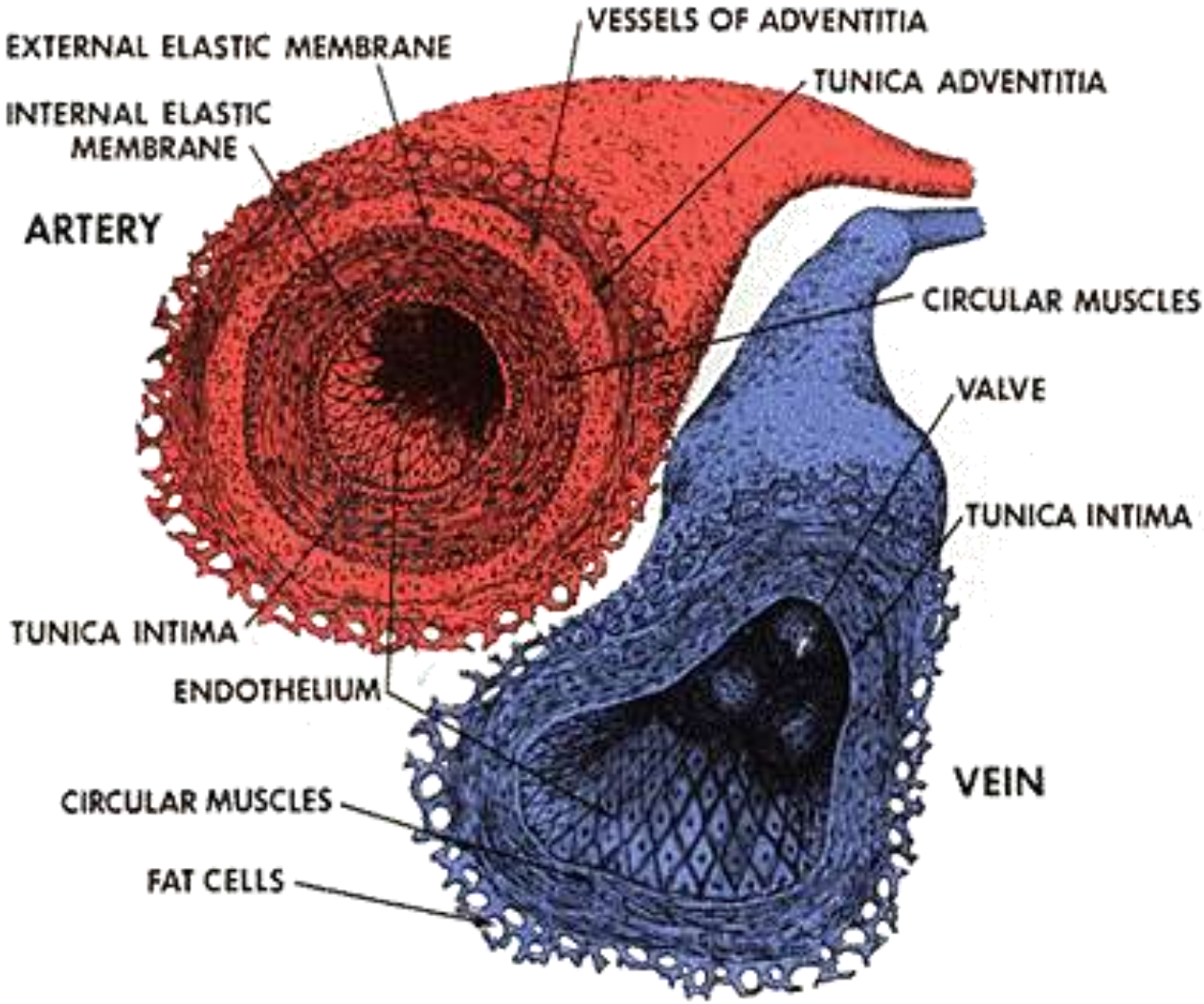
H.S. Cheerleader: “I’m not exactly sure. Does it go down the right leg and up the left?”

Jay Leno: “Can you name the three kinds of blood vessels?”



A freshman at UCLA: “Yes, arteries, veins and caterpillars.”

Anatomy of Artery and Vein

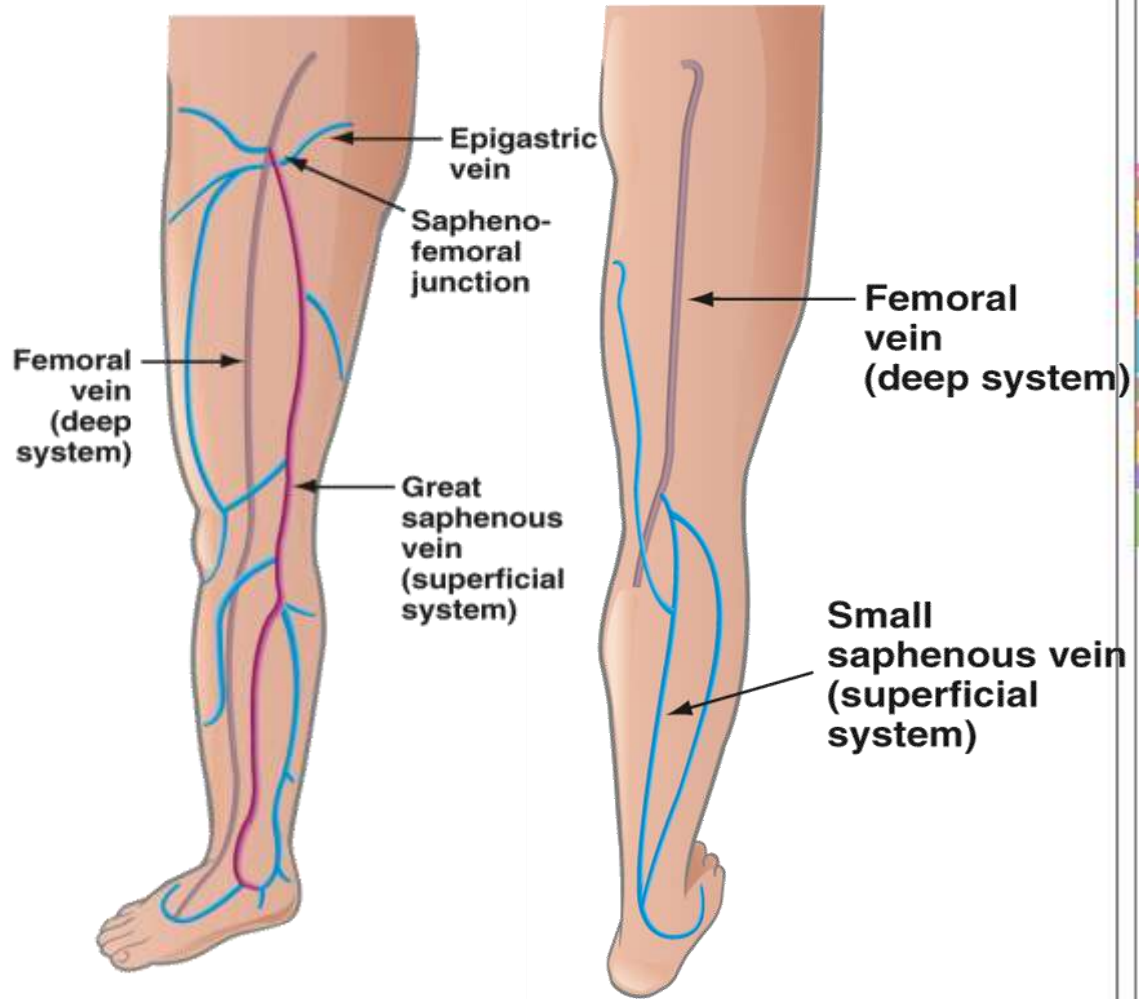


Vein



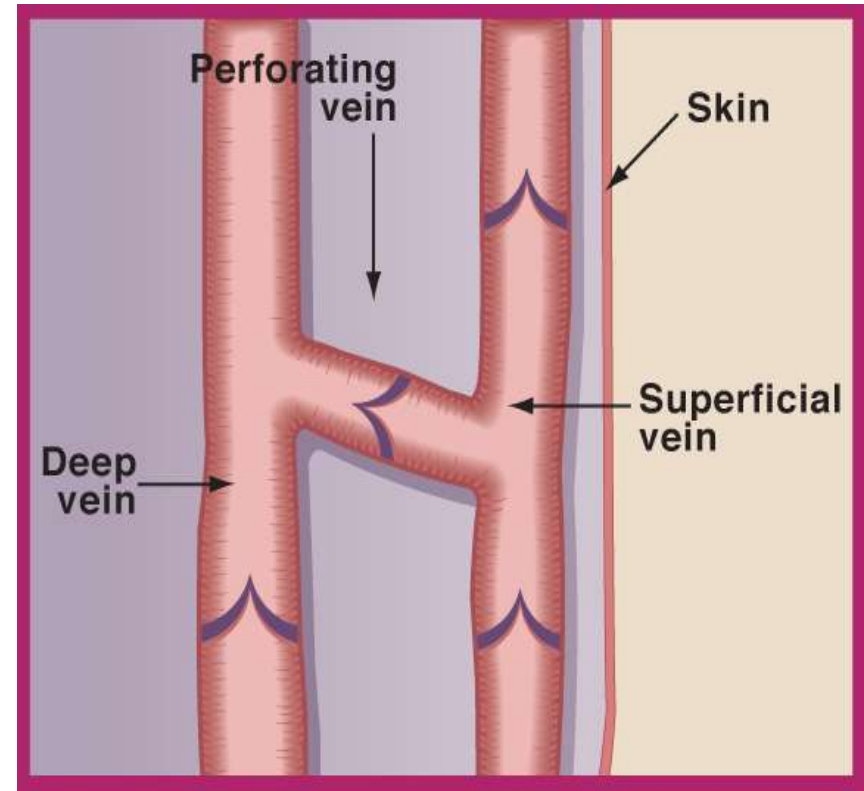
Leg Vein Anatomy

- Your legs are made up of a network of veins and vessels that carry blood back to the heart
- The venous system is comprised of:
 - Deep veins
 - Veins closer to the skin (superficial veins)

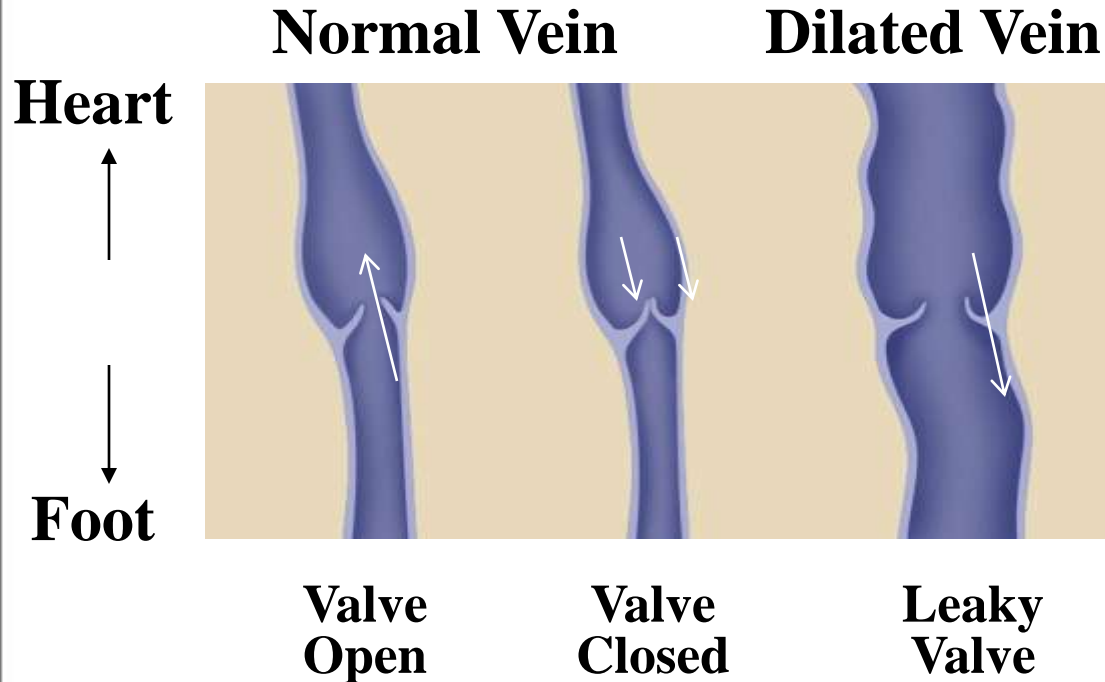


Leg Vein Anatomy

- Perforating veins connect the deep system with the superficial system
- They pass through the deep layer of muscular fascia tissue at mid-thigh, knee and ankle



Venous Reflux Disease



1. Vein valves become damaged or diseased, resulting in vein valve failure
2. Reflux or backward flow in the veins occurs
3. Pooling of blood causes pressure in leg veins
4. Increased pressure may cause surface veins to become dilated (varicose)

Varicose Veins

- Definition:
Veins which are very close together
(Norwegian)


Patient Demographics

- It is estimated that in America, 72% of women and 42% of men will experience varicose veins by the time they are in their 60s.¹
- Prevalence is highly correlated to age and gender
- Risk factors:
 - Multiple pregnancies
 - Family history
 - Obesity
 - Standing profession

¹ 1 Barron HC, Ross BA. Varicose Veins: A guide to prevention and treatment. NY, NY: Facts on File, Inc. (An Infobase Holdings Company); 1995;vii.

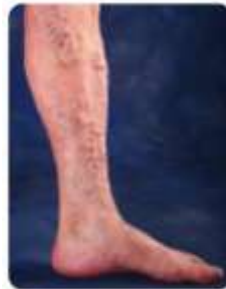- “Varicose veins are the result of an improper selection of grandparents.”

--Sir William Osler
1849-1919

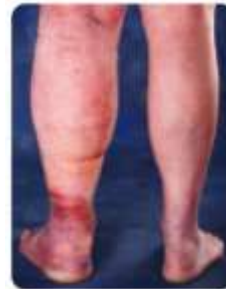

Symptoms

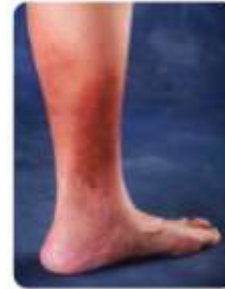- Approximately 24 million Americans suffer from venous reflux
- Common symptoms of this progressive condition include:
 - Varicose veins
 - Pain
 - Swollen limbs
 - Leg heaviness and fatigue
 - Skin changes and skin ulcers



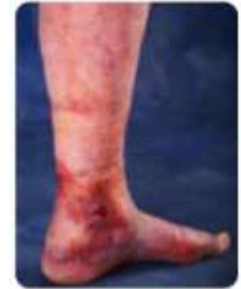Varicose Veins



Swelling



Skin Changes



Ulcers

Conservative Treatments

- Leg elevation
- Compression stockings
- Conservative treatments often have poor patient compliance because they:
 - are difficult for patients to integrate into daily routine
 - are uncomfortable
 - require lengthy (lifelong) treatment
 - do not cure the underlying problem (pathology)

Related and Complementary Procedures

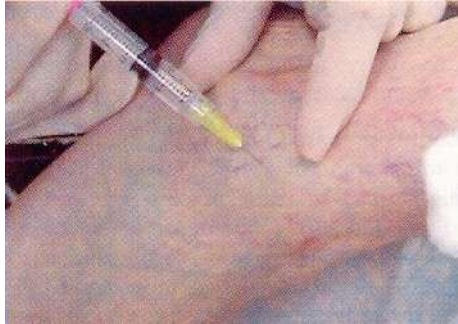

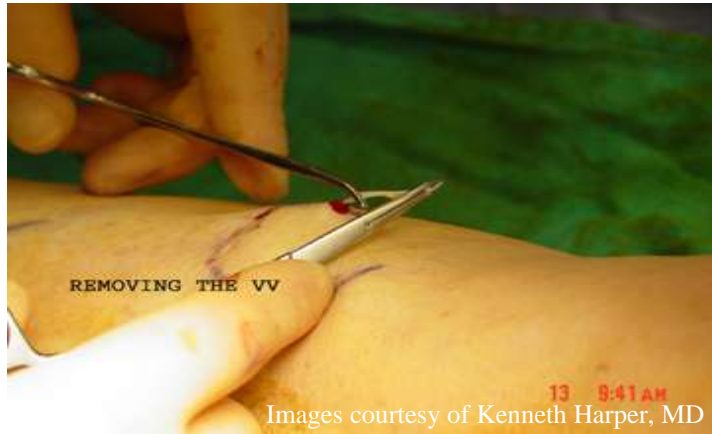
Image courtesy of Robert A. Weiss, MD

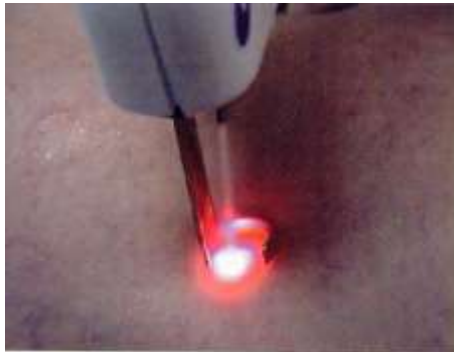

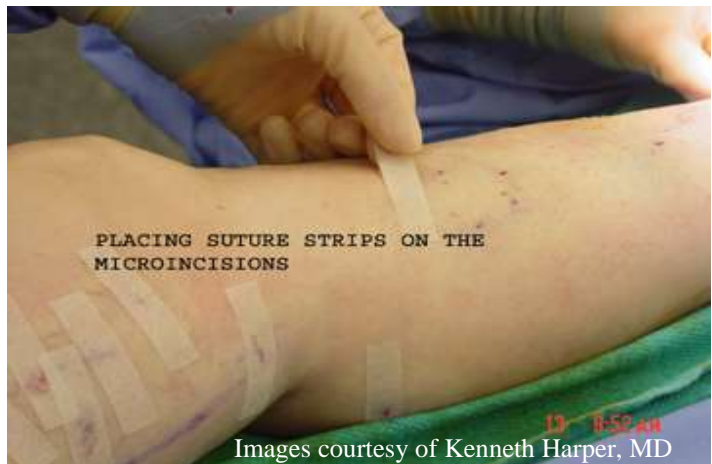Image courtesy of Robert A. Weiss, MD

- Sclerotherapy
- External lasers and intense pulsed light
- Used to treat small superficial or “spider” veins

Related and Complementary Procedures



- Phlebectomy
 - Removal of diseased veins through a series of small incisions and use of specialized hooks to treat visible varicose veins



- “We cannot direct the wind, but we can adjust the sails.”

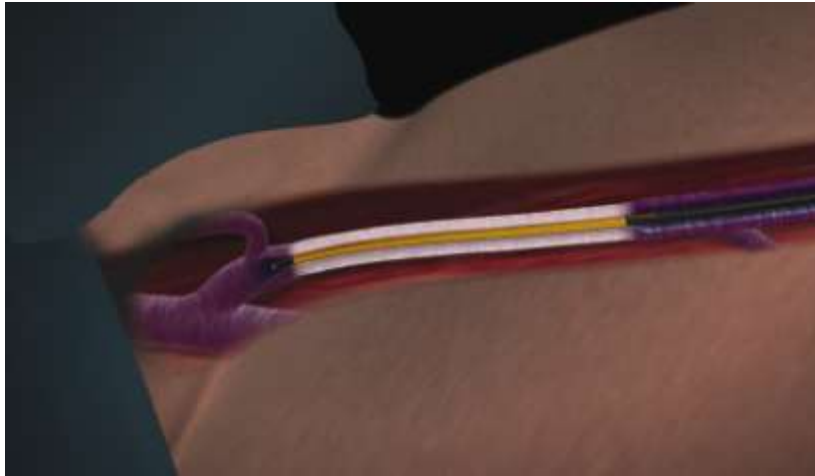
- Anonymous



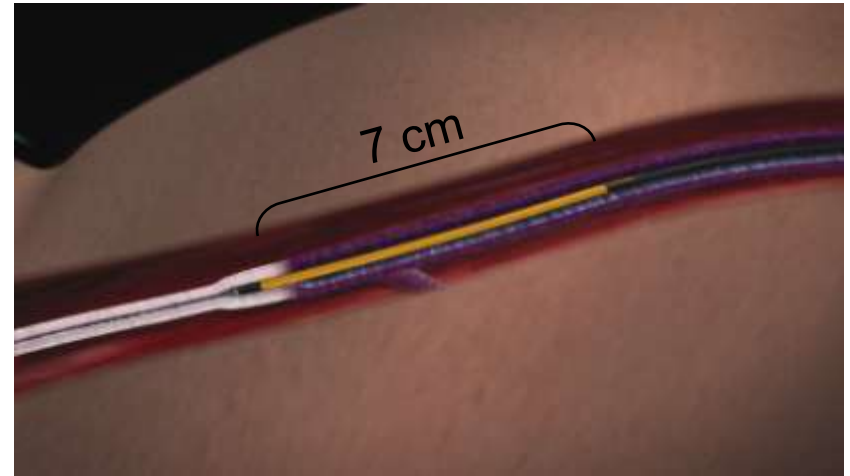
The VNUS Closure Procedure

Using the ClosureFAST™ Catheter

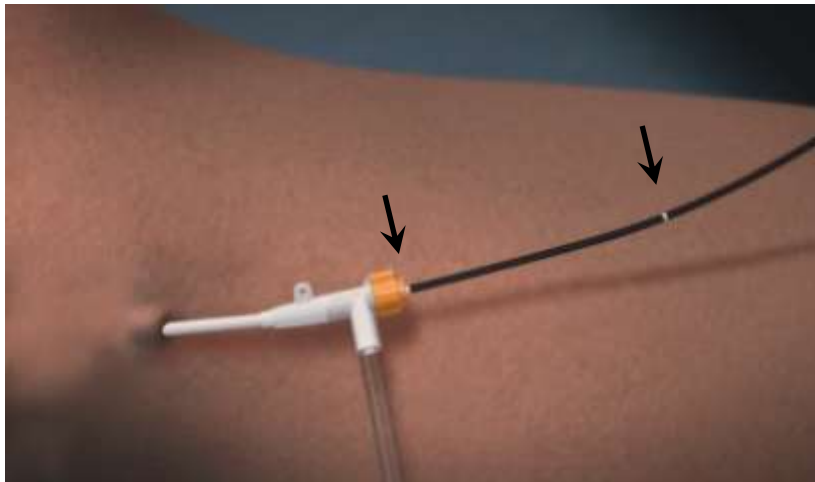
Catheter positioned at highest treatment point



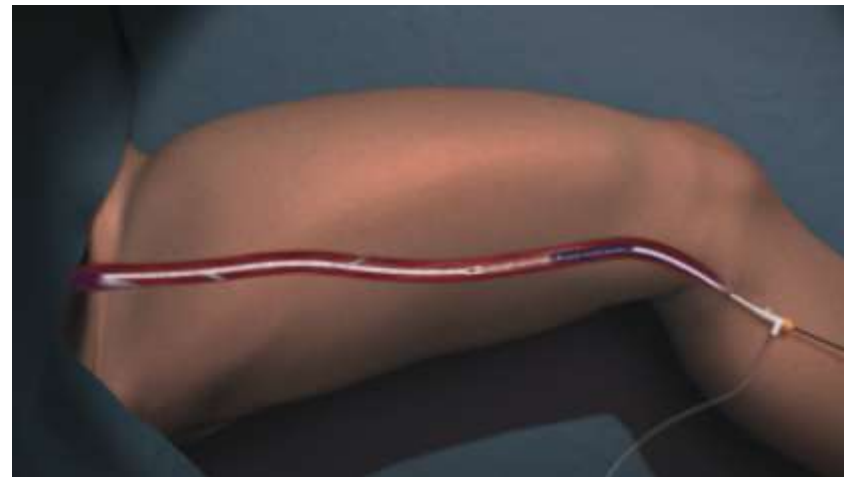
Vein treated in 7cm vein segments



Catheter withdrawn from marker to marker..



Until entire length of vein is treated



VNUS Closure Procedure Highlights



- Relief of symptoms
- Most patients resume normal activities within 1-2 days
- Outpatient procedure
- Local or general anesthesia
- Good cosmetic outcome with minimal to no scarring, bruising or swelling
- The VNUS Closure procedure is covered by most insurance providers

Safety Summary

- Indication:
 - The VNUS Closure System is intended for endovascular coagulation of blood vessels in patients with superficial venous reflux
- Contraindications:
 - Patients with a thrombus (blood clot) in the vein segment to be treated

Safety Summary

- Potential risks and complications include, but are not limited to, the following:
 - Perforation (hole through the wall of the vein)
 - Deep vein thrombosis (blood clot in one of the veins deeper in the leg)
 - Pulmonary embolism (blood clot that travels into the arteries of the lung)
 - Phlebitis (reddened, warm skin caused by blood clot in the vein)
 - Hematoma (collection of blood under the skin)
Adjacent nerve injury (numbness or tingling in the legs)
 - Infection
 - Skin burn

- Video